

By Conrad J. Rensburg

# The Evolution of Restoring Dental Implants: A CoCr Alloy Case Study

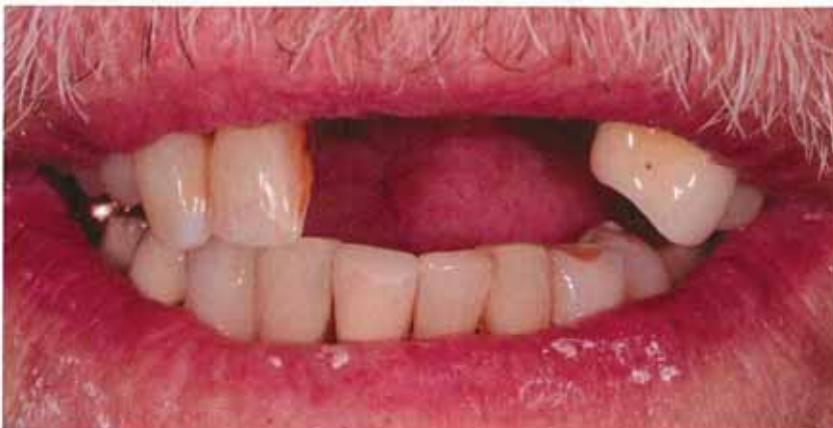**T**he ability to embrace and implement cutting edge technology gives today's dental lab the advantage needed to survive in an ever-changing market. In my more than 25 years in the dental technology industry, I have seen a definite shift from technicians being seen as the guy in the backroom making teeth to one of the most valued partners in the restorative team.



(Above) Dr. David Hedgecoe, Restorative Dentist

Today's exponentially evolving dental landscape is not only driven by technological advances, but also by new materials and innovative restorative options. This ever-changing market is causing a true demand for treating our patients with higher quality products and better restorative options. To survive in this new world, dental technicians are expected to not only be artists, but to be able to provide guidance on these new materials and protocols. Clinicians are bombarded by a multitude of restorative options mostly advertised by sales driven marketing. Technicians who are in the know and able to guide their customers can use this knowledge as a powerful marketing tool.

(Below) Pre-op



Technology is now allowing dental labs to be less dependent on human hands for the arduous tasks. Through these efficiencies, our industry—for the first time—is now becoming scalable. Unfortunately, this scalability also creates a more level playing field within the industry and with this comes price pressure from corporate labs.

Over the last few years, I have witnessed a definitive shift in our industry where posterior crowns, once considered the moneymakers, have become a mere commodity. I believe we will most likely see a complete eradication of most of these posterior prosthetics, made by human hand, over the next five to 10 years. In a world where fast turnarounds and low cost often trumps artistry, the only defense we, as dental artists, have is staying abreast of new protocols. This allows us to showcase our artistry through innovative products that cannot easily be substituted by machines.

As a lab owner, I have come to the realization that not adapting to this new environment will only lead to one thing: extinction.

Historically, restoring the edentulous arch has been reserved for removable labs, but with the advancements in implant dentistry the line between removable and fixed prosthetics has become much less defined. With the use of a diagnostic denture,

restoring the edentulous or partially edentulous arch with a fixed, clip or even hybrid prosthesis has become extremely predictable.

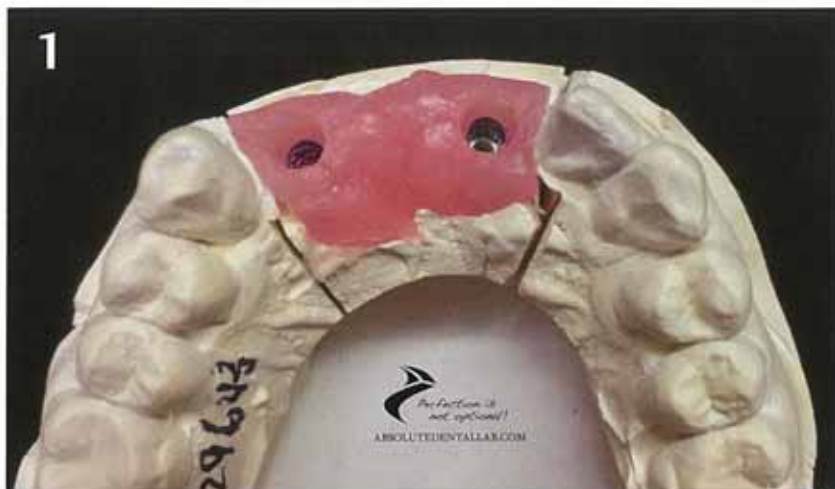
Hybrid restorative options have also evolved with the implant industry, but the restorative flow has stayed very much the same. In 2004, Nobel Biocare revolutionized restoring these patients with their all on four concept. Since then, we have seen a surge to find better long-term options in lieu of this traditional wrapped acrylic over a titanium bar. For many years, zirconia hybrids were considered a more stable long term option, but the inherent brightness of zirconia and the always lurking possibility of post-delivery fracturing has dampened the excitement we once saw for this material.

Milling facilities, like Dentsply Atlantis and others, are now also offering a third hybrid option, supra-structures, which are milled from a dental specific CoCr material. In conjunction with technologies like Angulated Screw Access (ASA), these hybrids can now be restored directly into the implant interface without having to consider the screw access position. ASA allows us to predictably fabricate full arch hybrids as well as posterior and anterior partially edentulous screw-retained prosthetics. In the near future, we expect this type of screw access technology to be available for single units.

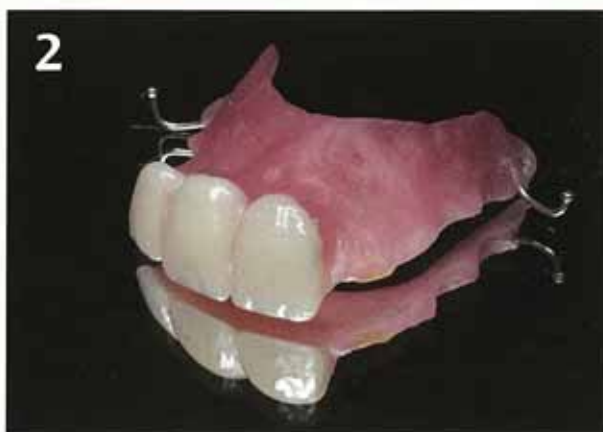With all the talk about peri-implantitis caused by cement, there is a definite drive in our industry away from two-piece CAD restorative options back to a simplified screw-retained solution. The pressure on laboratory technicians is mounting to find more economical yet still esthetic solutions, while maintaining profitability. This product fulfills all of the above requirements.

With the advancements in this alloy make-up over the last 10 years, today's dental CoCr offers an exceptional CTE, compatible with most all popular dental ceramics. Dental CoCr used by most manufacturers falls well within the acceptable range for dental ceramics of 14.0 to 14.9 fflm/m.K.

If we compare the Coefficient of Thermal Expansion of dental CoCr alloy to some of the most popular alloys on the market today (Argen Nobel NF - 14.4-14.8, Argident Euro White High Nobel - 14.1-14.4 & Argident Bio 880PF High Nobel Yellow - 14.2-14.4), it is easy to see why this alloy is so predictable under multiple firings.



**Figure 1**  
Soft tissue model



**Figure 2**  
Tooth try-in for structure design

Most ceramists who have worked with previous generations of CoCr alloys remember a thick green oxide layer causing greening and cracking in ceramics under multiple firings. This excessively thick oxide layer also caused de-bonding between the opaque layer and alloy.

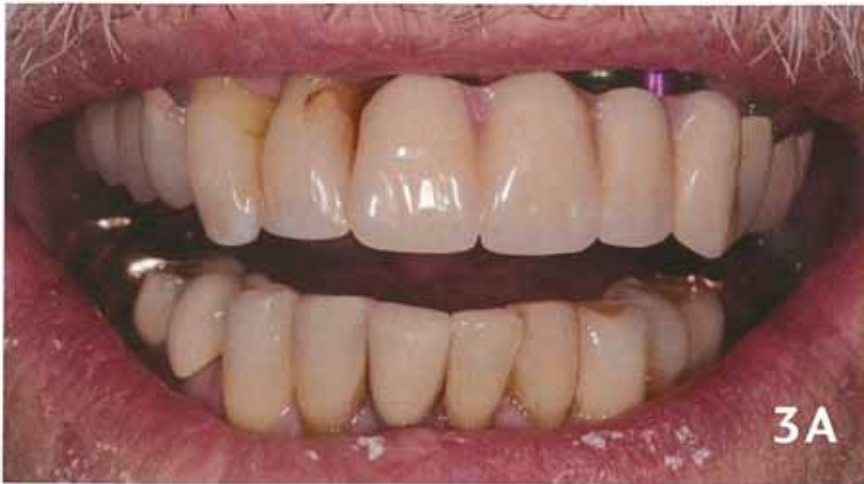Because of the eradication of nickel and beryllium from today's alloy, we achieve an excellent oxidation layer, creating an exceptional base for bonding and color. This type of support structure not only allows our ceramists to showcase their artistry, but the protocols we use to restore these cases have given my team and I a great marketing tool.

## Clinical Protocol

\*Please note that for explanation purposes, multiple cases are pictured.

## First Appointment

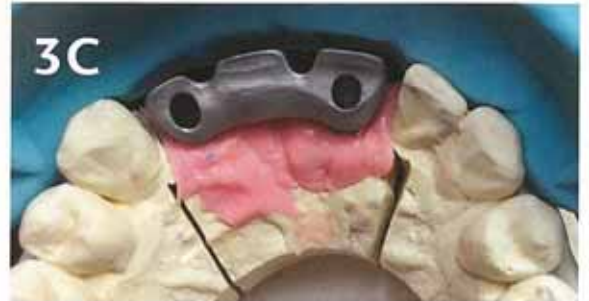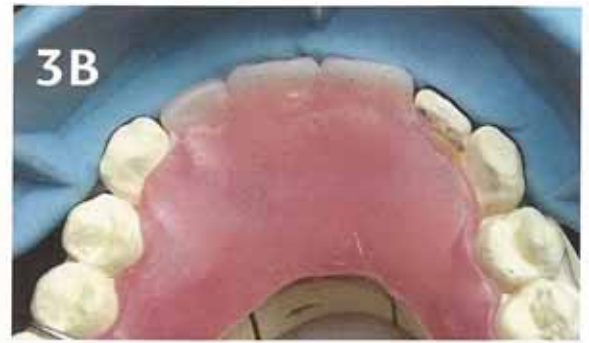
The clinician registers an implant level impression using digital or PVS media. The lab fabricates a soft tissue model (**Figure 1**) and a wax based tooth try-in on an acrylic base (**Figure 2**).



**Figure 3A**  
*Diagnostic denture try-in*

**Figure 3B**  
*Bucco-lingual parameters*

**Figure 3C**  
*Accurate metal support*



**Variation 1:** The laboratory technician can also fabricate an implant supported bite rim to establish a bite and model verification jig. Although valuable in posterior applications, most smaller anterior cases will not require an implant supported bite rim. A traditional metal framework try-in can be used in lieu of a verification jig.

**Variation 2:** If the patient has an acceptable temporary or partial flipper, a model of this approved tooth position can be used as a study cast to assist in fabricating the Atlantis supra-structure.

## Second Appointment

The clinician will do a tooth try-in (**Figures 3A-3C**) to determine patient expectations as well as to establish the bucco-lingual corridors and incisal edge position. This tooth try-in will be duplicated and used as a copy-mill design structure for the final CoCr supra-structure. An accurate tooth try-in contributes to precise

metal support and this in turn contributes to the long term success of the prosthesis. The tooth try-in will also be used by the ceramist as study cast for tooth position, shape and shade.

**Variation 1:** Clinician verifies model/impression accuracy by seating the model verification jig in the mouth. The clinician registers a bite with the supplied implant supported bite rim. The laboratory technician fabricates an implant supported tooth try-in on acrylic base.

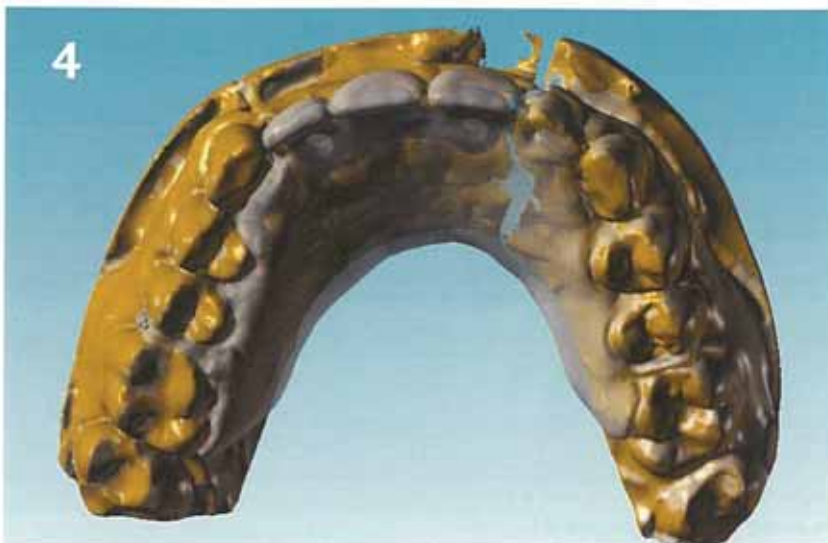**Variation 2:** If the patient has an acceptable temporary or partial flipper, a model of this approved tooth position can be used as study cast to assist in fabricating the alloy Atlantis support supra-structure. No tooth try-in or model verification appointment is necessary in this case.

**Atlantis Fabrication:** The laboratory technician will ship the models and tooth try-in to Atlantis Supra-structures for design and milling of the final metal support structure. Atlantis will return a digital work-up (**Figure 4**) of the case to the lab for potential changes and final approval. Once approval is received from the lab, Atlantis will mill the support structure (**Figures 5A-5D**) and return to the lab.

## Third Appointment:

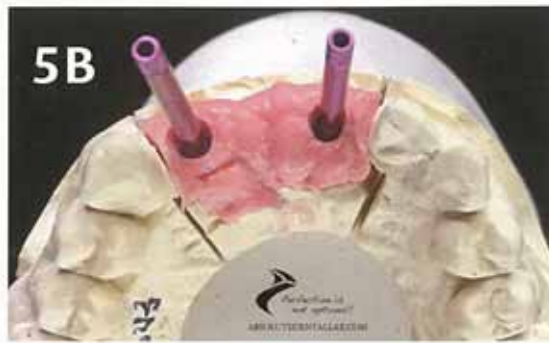Optional metal framework try-in (**Figure 6**) to verify model accuracy and fit. To reduce the possibility of internal connection implants

**Figure 4**  
*Digital dual scan for design*

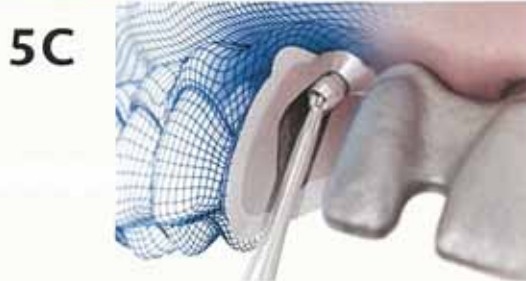



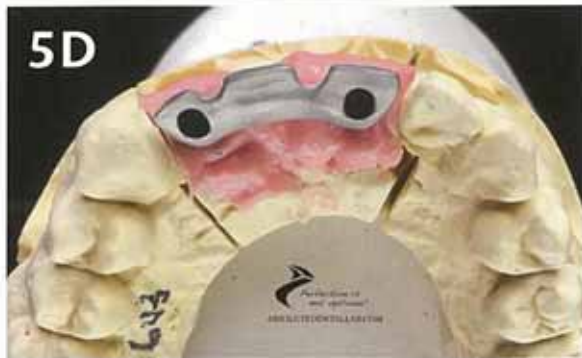5A



5B



5C



5D

**Figure 5A**  
Metal structure for try-in

**Figure 5B**  
Screw access is controlled with ASA technology

**Figure 5C**  
Atlantis ASA

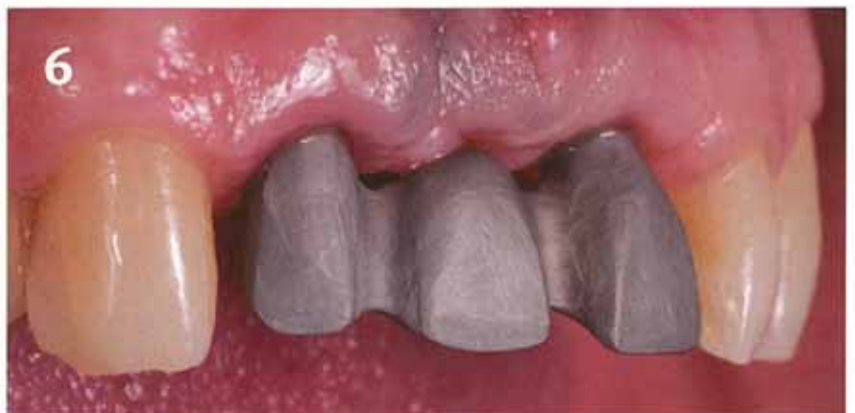**Figure 5D**  
Angulated screw access correction

creating undercuts, the Atlantis supra-structure does not engage the hex of the implants (Figures 7A and 7B). Seating is verified by complete integration between the internal axial wall of the implant and external axial wall of the structure.

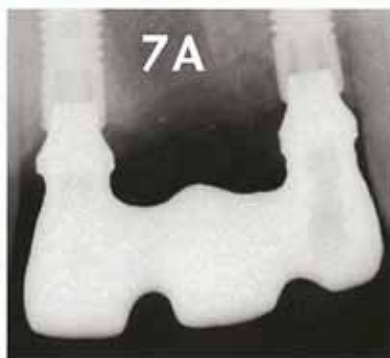**Variation 1:** Tooth try-in to establish desired bucco-lingual parameters, tooth shape and shade.

#### Fourth Appointment:

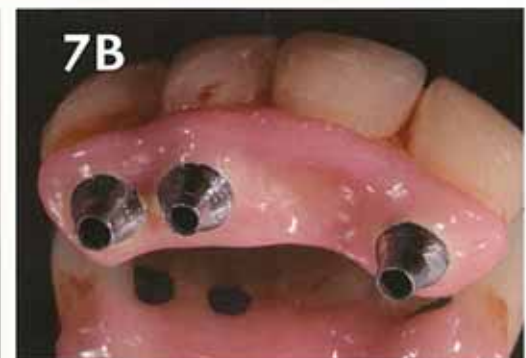Final delivery precisely matching the patient approved tooth try-in (Figure 8). Our master ceramist Yunsoo Kim (Figure 9) carefully shapes the pontic to allow for a natural emergence from the tissue. In this case, pink tissue was applied to create a natural emergence and control the



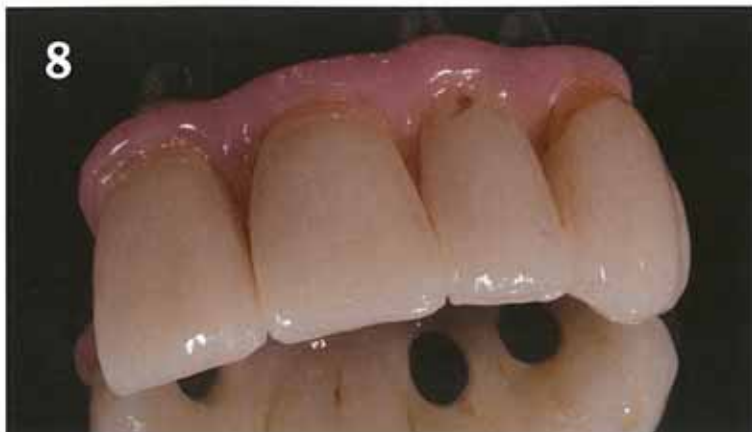6



7A



7B



8



9

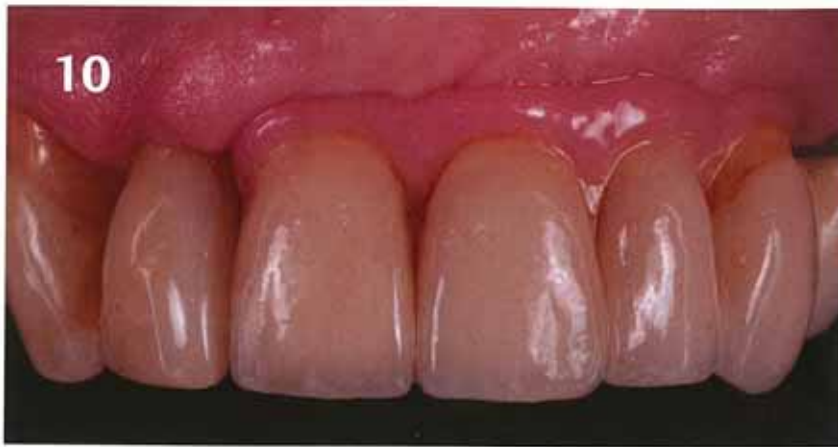**Figure 6**  
Frame-work try-in and model verification

**Figure 7A**  
Verifying fit

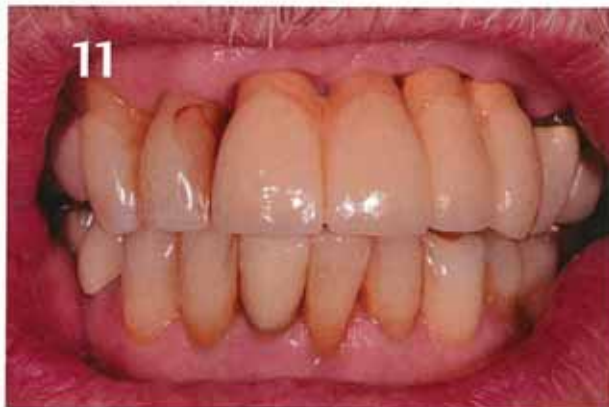**Figure 7B**  
Non hexed frame

**Figure 8**  
Screw access corrected prosthesis

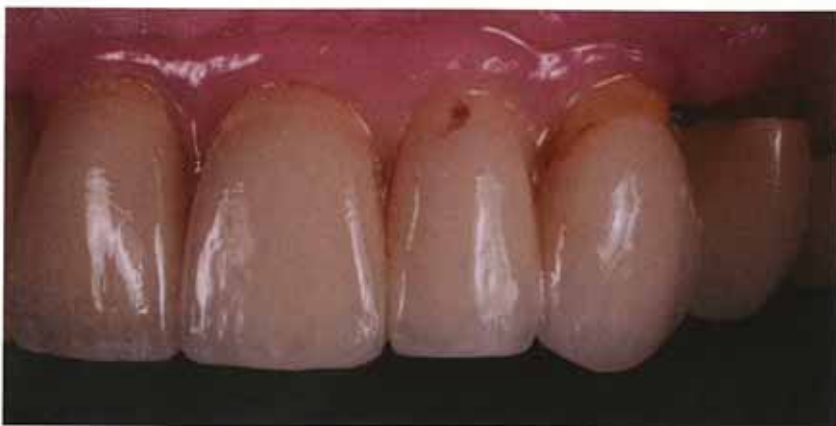**Figure 9**  
Yunsoo Kim, Absolute Master Ceramist



**Figure 10**  
Pink tissue applied to create natural emergence, length and line angles



**Figure 11**  
First attempt without pink tissue



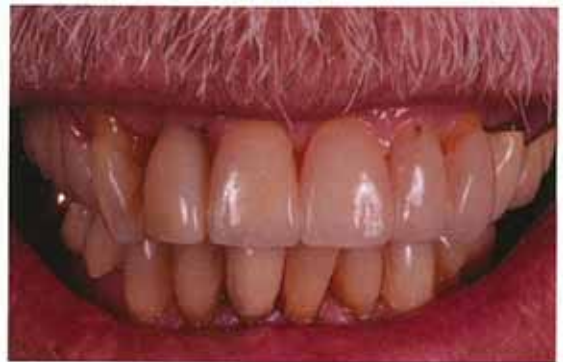(Above) CoCr Fixed Partial

coronal length of the teeth (Figure 10). Pink tissue is also very helpful to control tooth emergence and line-angles influenced by implant positions. The first attempt (Figure 11) to restore this case was done without pink tissue, making control over the emergence and neck positions an esthetic challenge.

**Variation 1:** Optional metal frame work try-in. If model is verified, no metal try-in is required.

### Fifth Appointment:

Final delivery of Variation 1. ●



(Above) Post-op final

### About the Author:

Conrad J. Rensburg graduated from Pretoria Tech under full scholarship with a four-year baccalaureate degree in dental technology. He has specialized in fixed dental prosthetics with an emphasis on dental implant restorations since 1993. As a CE-accredited speaker since 2002 for several U.S. dental implant companies, Rensburg has been the keynote speaker at special events across the U.S. His meetings focus on keeping restorative dentists up to date with the ever-changing protocols associated with restoring today's implant systems. He focuses on CAD implant design protocols and fixed and removable hybrid implant supported restorative techniques.



### Earn continuing education credits for this article and quiz!

Receive .5 hours CDT/RG scientific credit and .5 hours general credit towards your state of Florida dental laboratory renewal by reading this article and passing the quiz. To get your credit, complete the quiz located on the FDLA website at [www.fdma.net](http://www.fdma.net) using the *focus* Magazine link. Once you have completed the quiz, fax it to FDLA at 850-222-3019. This quiz is provided to test the technician's comprehension of the article's content and does not necessarily serve as an endorsement of the content by FDLA.

